

9-1977

Progressive ataxia and hearing loss (left) in a 23-year-old man. A clinico-pathological conference

Jose Bebin

Follow this and additional works at: <https://scholarlycommons.henryford.com/hfhmedjournal>



Part of the [Life Sciences Commons](#), [Medical Specialties Commons](#), and the [Public Health Commons](#)

Recommended Citation

Bebin, Jose (1977) "Progressive ataxia and hearing loss (left) in a 23-year-old man. A clinico-pathological conference," *Henry Ford Hospital Medical Journal* : Vol. 25 : No. 3 , 215-222.

Available at: <https://scholarlycommons.henryford.com/hfhmedjournal/vol25/iss3/10>

This Article is brought to you for free and open access by Henry Ford Health System Scholarly Commons. It has been accepted for inclusion in Henry Ford Hospital Medical Journal by an authorized editor of Henry Ford Health System Scholarly Commons.

Progressive ataxia and hearing loss (left) in a 23-year-old man. A clinico-pathological conference

Jose Bebin, MD, PhD*

As part of the scientific program honoring Robert S. Knighton, M.D., a clinical pathological conference was conducted by Dr. Jose Bebin.

Following presentation of the protocol, comments from several discussants included diagnoses of a primary neoplastic process in the brain stem, angioma of the pons, neoplasm or cyst of the posterior fossa, possible angioma on the left side of the brain stem, a viral cerebellitis, an ependymoma, or a medulloblastoma.

Together with the case presentation the author offers autopsy findings and a discussion and review of the literature.

A 23-year-old, right-handed black man was admitted to the Veteran's Administration Hospital (VAH), Jackson, Mississippi, obtunded and in a semicomatose state.

The patient, a laborer, was in his usual state of excellent health until approximately one year prior to admission, when he noted the gradual onset of progressive difficulty in walking characterized by loss of balance. Within three months he began experiencing blurred vision with episodes of diplopia, vague paresthesias of both legs, and a gradual hearing loss in the left ear. Seven months prior to admission he was seen in the outpatient clinic of the VAH when he demonstrated a marked tendency to stagger and was unable to walk without the aid of a cane. A month later, he was admitted to the VAH for evaluation and treatment.

He presented as an oriented, alert, cooperative, slender young black man who was wheelchair-bound, but appeared neither chronically nor acutely ill. Vital signs were normal. There was no cranio-facial-cervical anatomic abnormalities and examination results of the heart, lungs, and abdomen were normal. The visual fields were normal to confrontation and the optic discs were sharp. The pupils were equal, of normal size, and reactive to light and accommodation. Extraocular movements were full and there was no ptosis. Gross horizontal and vertical nystagmus were present with a rotary component in the primary position. The horizon-

* The University of Mississippi Medical Center, Jackson, Mississippi

Address reprint requests to Dr. Bebin at The University of Mississippi Medical Center, Jackson, Mississippi.

Bebin

tal nystagmus was made worse on right lateral gaze; a slight disconjugate movement was present on the left lateral gaze with the nystagmus more marked in the left eye than the right. Normal sensation and strength were present in the distribution of the facial nerve. A Rinne test was normal; the Weber test lateralized to the right.

Muscle bulk, tone, and strength were normal throughout and no atrophy, fasciculations, or abnormal movements were noted. Sensory examination showed touch, vibration and pin prick modalities were intact and there were no abnormalities of position sense or stereognosis. Reflexes were 3+ and symmetrical throughout. There was no ankle clonus or Babinski response; a bilateral Hoffman's reflex was present. A minor degree of past-pointing was present on the left along with a slight incoordination of the left finger-to-nose test. Questionable dysdiadochokinesia of rapid alternating hand movements was noted. Station was normal and the Romberg test was negative. He walked with a wide-based gait and was clearly ataxic with a tendency to fall toward the right.

Laboratory Findings

Hemoglobin was 15.3 gm% and a hematocrit 46%. A sedimentation rate, urinalysis, and sequential multiple analyzer examination of serum were normal. A sickle-cell prep, serum VDRL, LE prep, and ANA test were negative. An EKG and x-ray films of the skull and chest showed no abnormality. An intermediate PPD skin test for tuberculosis was negative. A lumbar puncture yielded crystal clear fluid under an opening pressure of 140 mm H₂O. Cerebrospinal fluid protein was 31 mg%, glucose 62 mg% (blood glucose 80 mg%), and one mononuclear cell was present per mm³. Gram, Kinyoun's, and India ink stains revealed no organisms and cytological examination of the fluid was negative. Cultures for bacteria and fungi yielded no growth. Spinal fluid protein electrophoresis showed a gamma globulin level

of 2.7 mg% (7.9% of total protein). Spinal fluid VDRL was negative.

A brain scan was unremarkable and waking and drowsy state EEGs were interpreted as normal. Audiograms confirmed a sensorineural loss on the left. Ophthalmology consultation revealed vision without glasses to be 20/30 right side and 20/24 on the left, without scotoma or muscle adduction weakness.

Bilateral brachial arteriograms were performed and a suspicious area was noted, suggesting a mass effect in the cerebellar vermis along the left side. A pneumoencephalogram and a vertebral arteriogram showed no abnormality.

An oral multivitamin preparation, thiamine, and prednisolone were prescribed without symptomatic improvement. Intramuscular injections of ACTH were administered for 14 days; no clinical improvement occurred. He was discharged from the hospital on crutches, to be followed in the neurology clinic.

Within three months his disability had progressively increased, and he went to another hospital.

Physical examination there showed he was oriented and alert with normal vital signs. Neurological examination was unchanged with the exception of definite impaired coordination of the left finger-to-nose and heel-to-knee tests, an intention tremor of the left hand, and muscle fasciculations at the left corner of the mouth. Laboratory examinations, including hemogram, urinalysis, serum and cerebrospinal fluid analyses, were normal. Repeat skull x-rays, pneumoencephalogram, and EEG were normal. A hemoglobin electrophoresis showed hemoglobin AS. Serum T3 and T4 studies were within normal limits. Audiograms were confirmatory of the previous examination, and he was discharged after a hospital stay of 78 days, with no medications prescribed.

Progressive ataxia

In the ensuing weeks he became progressively more ataxic with episodes of extreme lethargy. Appetite and fluid intake declined and he became less and less responsive to stimuli. He was referred to the VAH.

There was no past history of serious medical illness, head trauma, tinnitus, vertigo, sexual impotence, urinary hesitancy, or optic pain. His parents and six siblings were alive and well and there was no family history of cerebrovascular, seizure, or heritable neurologic disorder. Three years prior to admission he had experimented with the intravenous use of heroin for approximately one month, but had taken no drugs, other than prescription medications, since that time.

On arrival he presented as a dehydrated, semi-comatose young black man who responded only to painful stimuli with dysarthric, unintelligible speech. Temperature was 98.6 F, pulse 70 and regular, blood pressure 150/108 (left arm, supine). The pupils were equal and reactive to light; the fundi showed no evidence of papilledema. Bilateral horizontal and vertical nystagmus were present along with disconjugate eye movements in all directions of gaze. Questionable facial diplegia was present. Gag reflexes were decreased bilaterally. Motor examination showed decreased movement of the left side in response to painful stimuli. Reflexes were symmetrically 1 in the lower extremities and 2 in the upper extremities, without Babinski or Hoffman response. The lungs were clear and the heart regular, in rhythm without murmur. Bowel sounds were decreased but the abdomen was soft and without organomegaly.

Initial laboratory values included the following results: hemoglobin 18.2 gm%, hematocrit 53%, and WBC 11,400 with a normal differential. Serum Na⁺ measured 142 mEq/L, K⁺ 5.3 mEq/L, Cl⁻ 98 mEq/L, CO₂c.p. 28 mEq/L, creatinine 1.2 mg%, and osmolality 320 mOsm/Kg. Urine osmolality

measured 908 mOsm/Kg with a normal sediment. An x-ray film of the chest showed no change from previous studies.

The patient was hydrated with intravenous fluids with slight improvement in his sensorium occurring over the next several hospital days.

A lumbar puncture was performed on the eighth hospital day, yielding xanthochromic fluid under an opening pressure of 310 mm H₂O. A single lymphocyte and 88 RBCs were present per mm³. Cerebrospinal fluid protein measured 40.5 mg% and glucose 114 mg% (blood glucose 130 mg%). Stains and cultures for bacteria and fungi were negative.

A surgical procedure was performed on the ninth hospital day. For all practical purposes, it might be said that the patient expired before he ever reached the operating table.

Autopsy findings

The autopsy,* limited to the head, revealed no abnormalities in the cranium and dura mater. The brain weighed 1,350 grams, appeared edematous and congested. Herniation of the cerebellar tonsils was more marked on the left. The pons and the upper medulla were enlarged and flattened. The blood vessels of the circle of Willis were normal.

When the brain was sectioned coronally, the cerebral white matter and ventricles appeared symmetrical. A small needle tract from the right frontal region ended in the right frontal horn. At this level a small blood clot was noted, extending into the septum pellucidum. A small amount of blood was also present in the third ventricle and at the entrance of the cerebellar aqueduct.

* By Dr. Gatling, VA Hospital

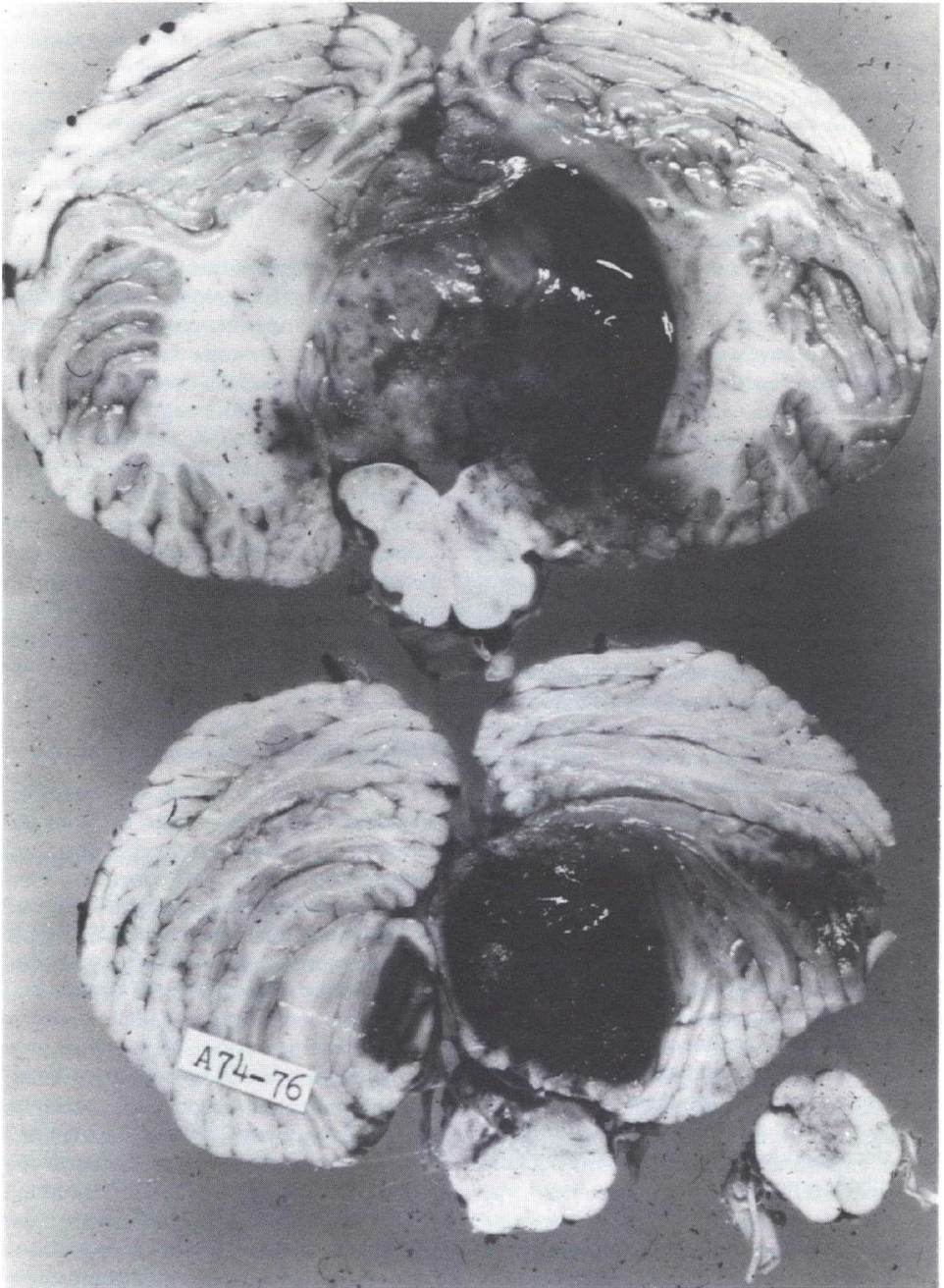


Figure 1

The tumor: A medulloblastoma of the right cerebellar hemisphere invaded the vermis, the cerebello-pontine angle and obliterated the fourth ventricle. A terminal hemorrhage is present within the neoplasm.

Progressive ataxia

The brain stem and cerebellum were sectioned horizontally. A large, partially necrotic and hemorrhagic gray-pink neoplasm measuring 4 x 4 x 3 cm was found in the cerebellum. The neoplasm involved the vermis and, laterally, both hemispheres, predominantly the left. The tumor also invaded the dorso-lateral portion of the pontine and medullary tegmentum, the middle and inferior cerebellar peduncles and the tonsil on the left side. It also obliterated the fourth ventricle.

Microscopic examination

The tumor was very cellular with areas of fresh hemorrhages. The tumor elements were deeply stained, predominantly arranged in islands surrounded by a fibrous connective tissue rich in reticulin. In some fields, the tumor cells were arranged in sheaths with little intervening connective tissue. In both instances, the neoplastic elements were the same. They contained round, oval, or slightly pear-shaped hyper-

chromatic nuclei with granular chromatin. Their cytoplasm was scanty and ill-defined and, when stained, appeared eosinophilic. Some degree of nuclear pleomorphism was present. Mitoses were numerous. No clear neuroblastic differentiation was noted, except for a tendency to form rosettes. Touch preparations of the tumor stained by the Papanicolaou method clearly demonstrated the individual neoplastic cells with their deeply-stained granular nuclear chromatin, occasional nucleoli and "carrot-shaped" forms. In some tumor cells protoplasmic processes indicated a neuroblastic differentiation.

Conclusion

This neoplasm is classified as a medulloblastoma of the "Desmoplastic" type described by Rubinstein and Northfield (1964)¹ because of the predominance of this pattern over the "classical" type which is also occasionally present.

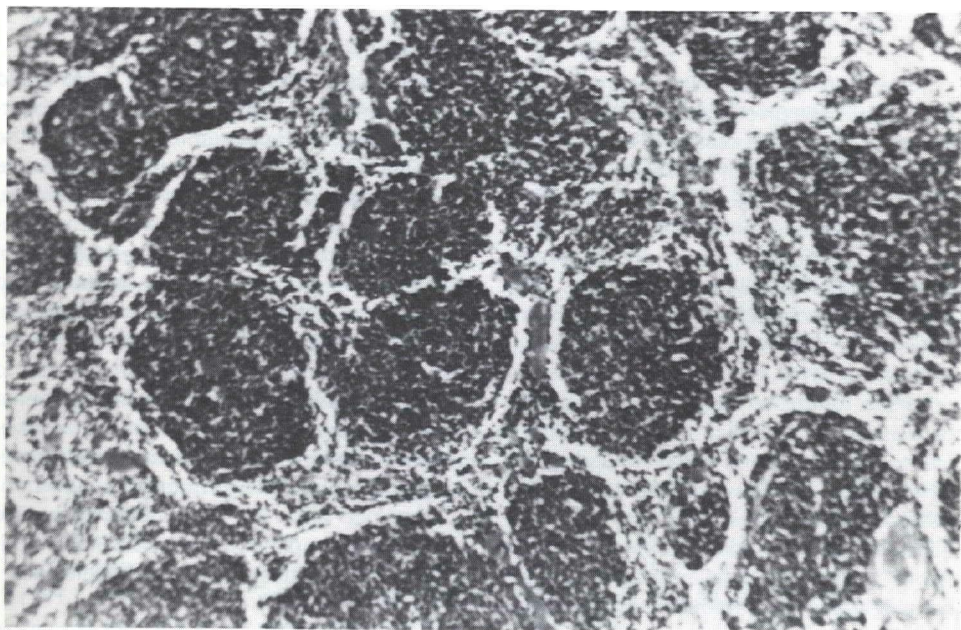


Figure 2

"Desmoplastic" type of medulloblastoma. The dark stained tumor cells are arranged in islands separated by trabeculae of connective tissue. H & E X115.

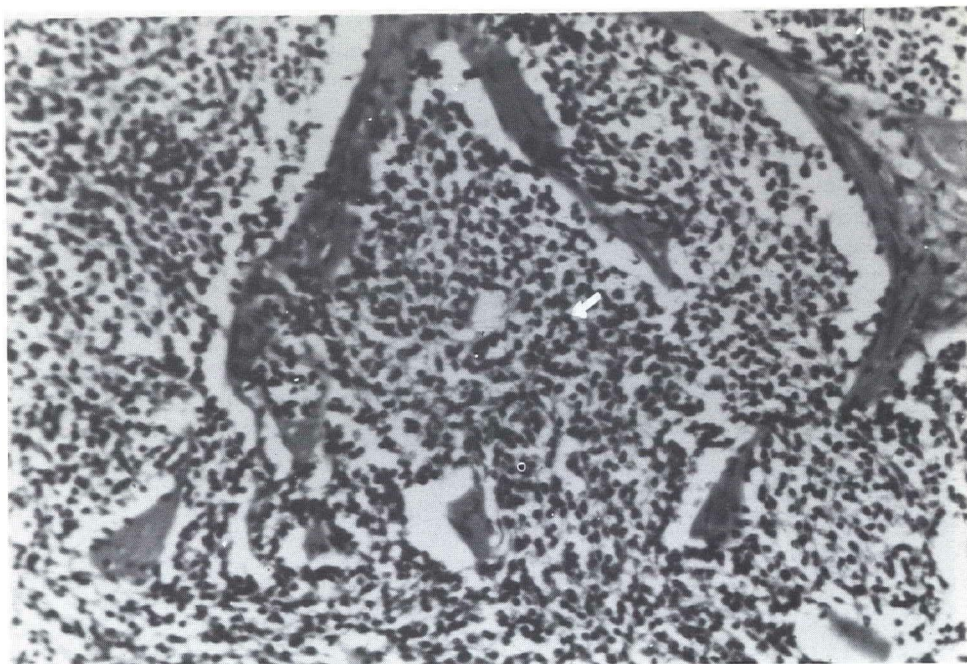


Figure 3
Islands of densely packed, deeply stained medulloblastoma cells. An occasional "rosette" (arrow) is seen in the field. H & E X200.

Some anatomical correlations are in order in this case. The presence of a large cerebellar tumor, a medulloblastoma of the "desmoplastic" type, is not unusual in an adult. Its extension into the brain stem, together with the partial obliteration of the fourth ventricle, produced a severe disturbance of the circulation of cerebrospinal fluid. This and the associated cerebral edema were responsible for the increased intracranial pressure of 310 mm H₂O. As frequently occurs in tumors of the posterior fossa, the herniation of cerebellar structures contributes to the aggravation of the clinical symptomatology. Progressive deterioration of the state of consciousness and vital signs is a consequence of the compression of the brain stem. It preceded the severe pulmonary complications (pneumonitis and emphysema) responsible for the patient's demise.

The neurological symptoms and signs present in this patient are related to the

nature, size and situation of the lesion found in the cerebellum and brain stem. The bilateral ataxia of the extremities as well as the ataxia of gait were expressions of progressive cerebellar involvement by the neoplasm, predominantly of the left hemisphere. Contributing to this disorder was the extension of the neoplasm into the brachium pontis and inferior cerebellar peduncle on the left side. The hearing loss on the left ear in association with the cerebellar symptoms seemed to indicate an involvement of the left cerebellar pontine angle and resulted from an involvement of the left eighth nerve and corresponding cochlear nuclei. The adjacent vestibular area was also infiltrated by the neoplasm, explaining the vertical and horizontal nystagmus present on the left side.

The cerebellar medulloblastomas were first described by Bailey and Cushing (1925)² as an embryonic tumor of the nervous system made up by primitive or poorly differen-

Progressive ataxia

tiated cells which they designated as medulloblasts.

Although their origin is still a matter of dispute, the idea widely accepted is that advanced by Stevenson and Echlin (1934)³ that the medulloblastoma arise from remnants of the external granular layer and normally persist in the infant cerebellum until after 18 months. Residual cell nests in the posterior medullary vellum account for the midline examples. These cells migrate laterally to form the external granular layer of the cerebellar hemispheres and account for the lateral situation of medulloblastomas occurring in adults.

Medulloblastomas constitute 6% of all intracranial tumors. They predominate in children in whom they constitute 25% of all intracranial neoplasms. Fifty percent occur in the first decade of life, mostly between the ages of 5 and 10 years; 30% occur in adolescents and young adults, between the ages of 15 and 35 years. They may also occur in adults up to the end of the fifth decade (the oldest example was a male age 61 at death). Males are more affected than females by a 4:3 ratio. The midline (vermis) examples are more common in children, while the lateral (hemispheric) cases occur in older age groups. Rubinstein and Northfield (1964) classified medulloblastomas in three histological types: 1) classical, 2) desmoplastic, and, 3) transitional. Their report included 42 medulloblastomas. The classical group included 22 cases (52%) usually situated in the vermis of the cerebellum, with average patient age under 15 years. Microscopic views were of a homogeneous, highly cellular tumor, with tumor cells closely packed and containing oval or carrot-shaped nuclei. They frequently show meningeal involvement.

The desmoplastic type included 12 cases (28%) occurring more frequently in adults and situated in the cerebellar hemispheres. They have a characteristic lobular or alveolar appearance with distinct pale islands of typical medulloblasts devoid of connective

tissue and surrounded by a thick connective network rich in reticulin fibers.

The transitional type included 8 cases (20%). This heterogeneous group linked the classical and desmoplastic varieties.

More recently, Chatty and Earl (1971)⁴ reviewed 201 medulloblastomas from several sources: Cleveland Clinic (W.J. Gardner surgical collection), University of Pennsylvania School of Medicine (Frazier-Grant tumor collection) and AFIP collection. Their emphasis is on the relationship of the histological variants of medulloblastoma to survival. Of the 201 medulloblastomas, 42 were desmoplastic and 152 were classical. No cases were classified as transitional in order to simplify the study. One hundred and five patients who had sufficient pathological and clinical data were treated by surgery and radiotherapy.

The average survival was 25 months for the entire group; 67 children (15 years or under) had an average survival of 11 months; 38 adults (16 years or over) survived an average of 50 months.

The location of the medulloblastoma was also of significance. The average survival for patients with midline tumors (78 cases) was 17 months, while those with hemispheric neoplasms (27 cases) was 47 months.

The histological typing of the tumor was also important. Patients with desmoplastic medulloblastomas had an average survival of 50 months; those with the classical medulloblastomas an average of only 18 months.

The majority of desmoplastic medulloblastomas occurred in adults and were located in the cerebellar hemispheres; those with the classical variety were mostly in children with midline (vermis) location.

These findings are in agreement with those reported previously by Rubinstein and Northfield.¹

References

1. Rubinstein LJ and Northfield DW: Medulloblastoma and the so-called "arachnoidal cerebellar sarcoma." *Brain* **87**: 379-412, 1964
2. Bailey P and Cushing H: Medulloblastoma cerebelli common type of midcerebellar gliomas of childhood. *Arch Neurol Psychiat* **14**:192-224, 1925
3. Stevenson L and Echlin F: Nature and origin of some tumors of the cerebellum — medulloblastoma. *Arch Neurol Psychiat* **31**:93-109, 1934
4. Chatty NE and Earle KM: Medulloblastomas. A report of 201 cases with emphasis on the relationship of histological variants to survival. *Cancer* **28** :977-984,1971